

Duplex Ultrasound Investigation of the Veins in Chronic Venous Disease of the Lower Limbs—UIP Consensus Document. Part I. Basic Principles

P. Coleridge-Smith,^{1*} N. Labropoulos,² H. Partsch,³ K. Myers,⁴ A. Nicolaides⁵
and A. Cavezzi⁶

¹London, UK; ²Chicago, IL, USA; ³Vienna, Austria; ⁴Melbourne, Australia; ⁵Nicosia, Cyprus;
and ⁶San Benedetto del Tronto, Italy

Objectives. Duplex ultrasound investigation has become the reference standard in assessing the morphology and haemodynamics of the lower limb veins. The project described in this paper was an initiative of the Union Internationale de Phlébologie (UIP). The aim was to obtain a consensus of international experts on the methodology to be used for assessment of veins in the lower limb by ultrasound imaging.

Design. Consensus conference leading to a consensus document.

Methods. The authors invited a group of experts from a wide range of countries to participate in this project. Electronic submissions from the experts were made available to all participants via the UIP website. The authors prepared a draft document for discussion at a UIP Chapter meeting held in San Diego, USA in August 2003. Following this meeting a revised manuscript was circulated to all participants and further comments were received by the authors and included in subsequent versions of the manuscript. Eventually all participants agreed the final version of the paper.

Results. The experts have made detailed recommendations concerning the methods to be used for duplex ultrasound examination as well as the interpretation of images and measurements obtained. This document suggests a methodology for complete assessment of the superficial and perforating veins of the lower limbs, including recommendations on reporting results and training of personnel involved in these investigations.

Conclusions. The authors and a large group of experts have agreed a methodology for the investigation of the lower limbs venous system by duplex ultrasonography.

Keywords: Consensus document; Duplex ultrasonography; Venous system; Chronic venous disease.

Introduction

Duplex ultrasonography is probably the most frequently used investigation to evaluate the venous system for the management of chronic venous disease (CVD) of the lower limbs. The results of many forms of treatment have been evaluated by duplex ultrasound and published in the medical literature. However, there is currently no systematic consensus agreement from phlebology or vascular societies on how duplex ultrasound for CVD is best performed. The aim of the document is to summarise best practices for venous duplex ultrasound examination of the lower limbs agreed upon by a group of clinicians who regularly use this

technology in their daily practice. Where possible, this has been based on objective information from the literature in addition to personal practice.

Methodology

The Union Internationale de Phlébologie (UIP) is an international organisation to which national societies of phlebology may subscribe as members. This society promotes scientific research and good clinical practice in venous disease through a number of initiatives including international congresses, sponsored research grants and consensus development meetings. Recent consensus publications have included a nomenclature of the lower limb veins¹ and proposals for the revision of the CEAP classification² which led to the recent publication of a revised CEAP classification.³

*Corresponding author. Philip Coleridge Smith, DM, FRCS, Thames Valley Nuffield Hospital, Wexham, Bucks SL3 6NH, UK.
E-mail address: p.coleridgesmith@ucl.ac.uk

The UIP wished to promote a consensus on methods of investigation and interpretation of duplex ultrasonography in venous disease and invited three authors (AC, PCS, NL) to gather a group of international experts on duplex ultrasound in CVD. The Consensus Group acted individually to provide personal opinions that did not necessarily reflect policies of scientific or medical societies to which they may have been affiliated. The experts were invited to submit contributions that they felt encapsulated important aspects of clinical practice of duplex ultrasound examination of the venous system. Electronic submissions made by the experts were made available to all participants via the UIP website. The submissions included references to papers, photographs, diagrams and suggested text for the consensus document. The references provided during this process were not intended to form a systematic review of the literature but were selected to support statements made in the final document where evidence exists. The authors acknowledge that many of the statements concern subjects, which have not been the subject of detailed scientific study and reflect the personal practice of the experts. The organisers prepared a draft document that was placed on the UIP website, and this was discussed and further submissions and recommendations were made. Many of the experts and the organising committee as listed at the end of this document met at a chapter meeting of the UIP in San Diego in August 2003 to discuss the consensus documents and other submissions. A further draft of the document was then circulated to all contributors who again added their comments. A final document was agreed amongst all experts after further revisions of the manuscript.

The authors consider that the methodology above achieved a credible consensus process. The references in the document are intended to support statements and are not intended to be an exhaustive review. The Consensus Group gave consideration to using a formal assessment of every clinical study quoted to classify it according to clearly defined levels of evidence. This approach was rejected because few studies with high levels of evidence have been published in this area. Recommendations are based on available evidence and the combined clinical experience of the Consensus Group.

The authors suggest that implementation of the recommendations should be performed according to the facilities available in individual institutions. We envisage that our this document should form the basis of local protocols rather than an inflexible set of instructions.

Aim of the duplex ultrasound examination

The duplex ultrasound examination in patients with CVD should demonstrate both the anatomical patterns of veins and abnormalities of venous blood flow in the limbs. The following data should be established:

- (1) Which saphenous junctions are incompetent, their locations and diameters.
- (2) The extent of reflux in the saphenous veins of the thighs and legs and their diameters. The number, location, diameter and function of incompetent perforating veins.
- (3) Other relevant veins that show reflux.
- (4) The source of filling of all superficial varices if not from the veins already described.
- (5) Veins that are hypoplastic, atretic, absent or have been removed.
- (6) The state of the deep venous system including competence of valves and evidence of previous venous thrombosis.

Explanation

Most patients undergoing duplex ultrasound to investigate the superficial, deep and perforating veins are being considered for treatment of varicose veins. Information provided by the investigation will usually have a significant impact upon whether the treatment is offered and the type of treatment considered most appropriate. Patients with incompetent saphenofemoral or saphenopopliteal junctions may be offered surgery, (duplex-guided) sclerotherapy or an endovenous procedure (radiofrequency closure or endovenous laser therapy). Those with isolated incompetence of saphenous tributaries could be treated by phlebectomy or sclerotherapy. Failure to identify and treat all sources of venous filling is likely to result in early recurrence of varices.

The Duplex Scan

Indications for duplex scanning

Since venous reflux commonly affects both limbs, it is recommended that both limbs be studied at the initial investigation, even if only one shows evidence of venous disease although this is dependant on the resources of the diagnostic service.

Primary uncomplicated great saphenous territory varicose veins

Whether all patients require scanning is debated.^{4,5} Clinical assessment with or without pocket (continuous wave, CW) Doppler will miss up to 30% of important connections from deep to superficial veins and information on affected veins when compared to duplex scanning.⁶

Primary uncomplicated small saphenous territory varicose veins

Duplex scanning is considered to be essential prior to treatment to determine whether there is a saphenopopliteal junction (SPJ), to record its level, and to show complex anatomy such as a common insertion with the gastrocnemius veins.⁷⁻⁹

Non-saphenous varicose veins

Veins such as those related to pelvic/perineal vein reflux, varices unrelated to the great or small saphenous veins, or isolated lateral thigh varicose veins will be demonstrated to indicate that saphenous ligation or stripping may not be required.

Recurrent varicose veins

Duplex scanning is considered to be essential to establish the complex anatomy and haemodynamics of recurrent varices to show whether surgery or endovenous treatment is appropriate.¹⁰⁻¹²

Chronic venous disease with complications

Duplex scanning is considered to be essential to assess the relative involvement of the deep and superficial venous systems to predict the likely outcome after treating superficial disease alone and to select patients suitable for consideration of deep venous reconstruction.

Duplex ultrasound surveillance after treatment

This may be used to assess the outcome of therapy and for early detection of recurrence.¹³ This is likely to be the only way to obtain level I evidence as to outcome in the future.

Venous malformations

Duplex ultrasonography may be used to investigate and provide good management for vascular malformations (angiomas). The investigation provides anatomical information about the extent of the malformation and its relationship to other vessels in the affected limb.¹⁴ It may also be used to guide treatment of malformations by sclerotherapy.¹⁵ It is frequently a prelude to further investigation by magnetic resonance imaging.

Explanation

Duplex ultrasonography can localise and specify the source of the venous problem to provide a map to help select best treatment and evaluate outcome for the venous problems discussed above.

Machine requirements and settings

A colour duplex ultrasound machine is recommended for this investigation.

A high-frequency linear array transducer of 7.5–13 MHz is appropriate for most lower limbs to obtain good quality images of superficial veins. A curvilinear array transducer of 3.5–5 MHz can be useful for very large or oedematous limbs.

B-mode machine settings

Superficial veins normally lie 1–3 cm below the skin. They are usually imaged in the longitudinal view with the proximal end of the veins to the left of the screen, and in the transverse view with the lateral aspect of the right limb and medial aspect of the left limb shown to the left of the screen. The focal zone for the transducer should be set at an appropriate level to obtain the best B-mode image of the vein under investigation. Gain and dynamic gain control (DGC) should be set to optimise the image so that the lumen of the vein should be dark in the absence of acute or chronic thrombosis and very slow flow (for cell aggregates can give spontaneous contrast), but to allow echoes from thrombus to be seen from within the lumen.

Pulsed-wave spectral or colour Doppler settings

The use of 'low flow' settings is recommended to optimise the machine for low flow velocities encountered within veins. Set the Doppler range to 5–10 cm/s with the wall filter at its lowest setting. It is best to increase the Doppler gain to show a small amount of 'noise' in the colour or pulsed Doppler signal to ensure maximum sensitivity of the system. It is advisable to increase the Doppler range and decrease the colour gain in patients with high venous flow to avoid significant colour artefact. It is conventional to use blue to represent orthograde venous flow towards the heart in the colour mode and red for the reverse (venous reflux) direction.

Position of the patient and probe

In order to standardise measurements of venous diameter and reflux, it is recommended that examination of the superficial veins is performed with the patient standing. The horizontal position is inappropriate for detection of reflux and measurement of vein diameters. However, both the lying and standing

positions have been reported in the published literature.

Examination of calf veins is usually best performed with the patient in either the sitting or standing position, according to the structures that are to be scanned (Fig. 1). Transverse and longitudinal views of the veins should be employed in duplex ultrasound scanning of the lower limbs. The transverse view gives more precise general information regarding morphology and possible presence of endoluminal thrombus through the compression manoeuvre, while a longitudinal view helps to assess orthograde flow and venous reflux more accurately. An angle of insonation of 45–60° between the transducer and vein should be used to achieve the optimum colour or spectral Doppler signal.

Examination for reflux

Definition of venous reflux

Venous reflux is considered to be retrograde flow in the reverse direction to physiological flow lasting for more than 0.5 s,^{16,17} though a definitive cut-off for all vein segments has not been agreed in the published literature.

Several methods are used to elicit reflux:

- Release after a calf squeeze for proximal veins or foot squeeze for calf veins.
- Manual compression of vein clusters.

- Pneumatic calf cuff deflation.¹⁸
- Active foot dorsiflexion and relaxation.
- The Valsalva manoeuvre—this may be the preferred technique to demonstrate saphenofemoral incompetence.

Venous reflux is elicited by imaging the vein under investigation whilst applying compression to the limb using one of the methods described above. The compression is abruptly removed and the presence and duration of reflux observed. Pneumatic cuff deflation has been used to permit quantitative assessment of reflux.¹⁸ This may be the most reproducible although some find it technically more difficult. Some experts consider that a Valsalva manoeuvre is more appropriate to test valvular competence at the sapheno-femoral junction.

Prepare the patient

The patient is examined in a room with sufficient lighting to enable thorough evaluation of the lower limbs and establish the distribution of varices.

The lower limbs are inspected for varicosities and scars from surgery to help predict the source of reflux and facilitate the examination. It is necessary to explain to the patient what is going to be done, particularly the Valsalva manoeuvre.

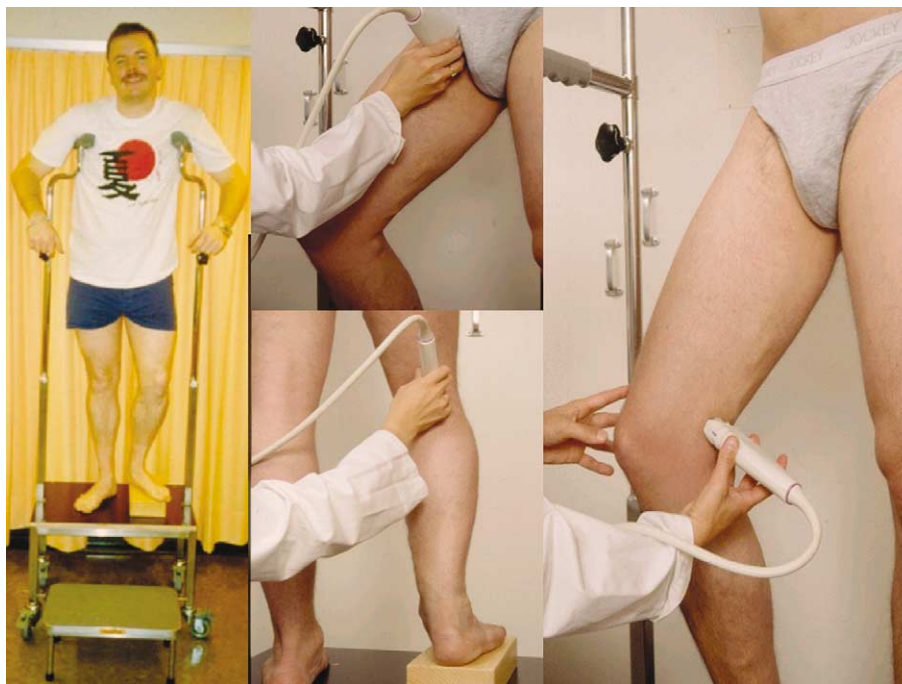

Fig. 1. Position of patient and probe during duplex ultrasound examination of the lower limb (Courtesy by K. Jaeger, Basle).

Reflux is more likely to develop later in the day, especially for non-dilated vein segments. A warm environment helps to make veins dilate, while a cold environment can cause them to constrict making them difficult to see so that borderline venous reflux may disappear. The lower limb under investigation must be relaxed during imaging to allow good venous filling in the calf veins.

Fig. 2 shows the approximate surface positions of the major superficial veins which will be examined.

Protocols for scanning the great saphenous vein (GSV), deep veins above knee and thigh perforators

Position of the patient

The patient should stand facing towards the examiner with the leg rotated outwards, heel on the ground and weight taken on the opposite limb.

The great saphenous vein (GSV) and accessory saphenous veins

Start the scan in the groin of the first limb to be examined. Use a transverse view to identify the GSV and the common femoral vein, both lying medial to the common femoral artery, using the 'Mickey Mouse' sign (Fig. 3). If the junction is not present after surgery to remove the GSV, then 'Mickey's' medial ear is

missing. Several veins can be visualised in the region of the saphenofemoral junction (SFJ) and two GSV valves (terminal and pre-terminal) can be imaged near the SFJ. It is important to assess these tributaries and GSV valves as several haemodynamic patterns can be seen.¹⁹

Assess possible sources of reflux or proximal points of insufficiency including SFJ incompetence, veins from the lower abdomen or pelvis, thigh or calf perforators, or the vein of Giacomini.

In the transverse view, determine whether the destination for reflux is into: (a) the GSV within the saphenous compartment, (b) into the accessory anterior saphenous vein (AASV) which is slightly external to GSV and aligned with the femoral vessels below, or (c) to major thigh tributaries superficial to the saphenous fascia. A connection between the GSV and pelvic sources of venous reflux is suspected if there is sudden increase in the GSV diameter, whereas the diameter may decrease distal to a major incompetent tributary. It is also recommended to scan within the inguinal lymph node area distal to the SFJ where normal and varicose veins may lie.²⁰

Follow the full length of the GSV or tributaries to the ankle. This vein lies within a fascial compartment which can easily be identified on the B-mode ultrasound image (Fig. 4). This appearance is widely

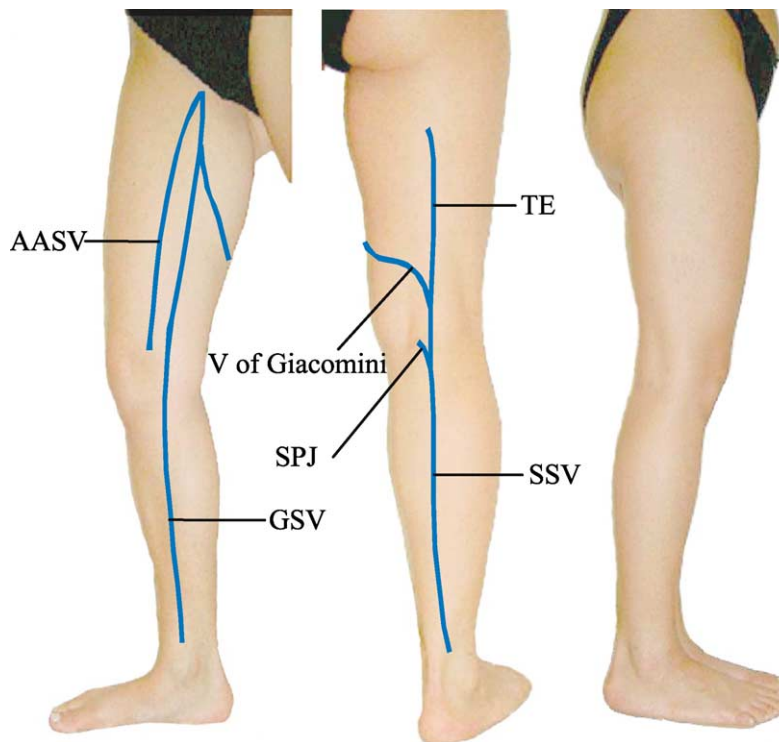


Fig. 2. Surface distribution of major superficial veins. AASV, anterior accessory saphenous vein; GSV, great saphenous vein; TE, thigh extension of the small saphenous vein; SPJ, sapheno-popliteal junction; SSV, small saphenous vein.

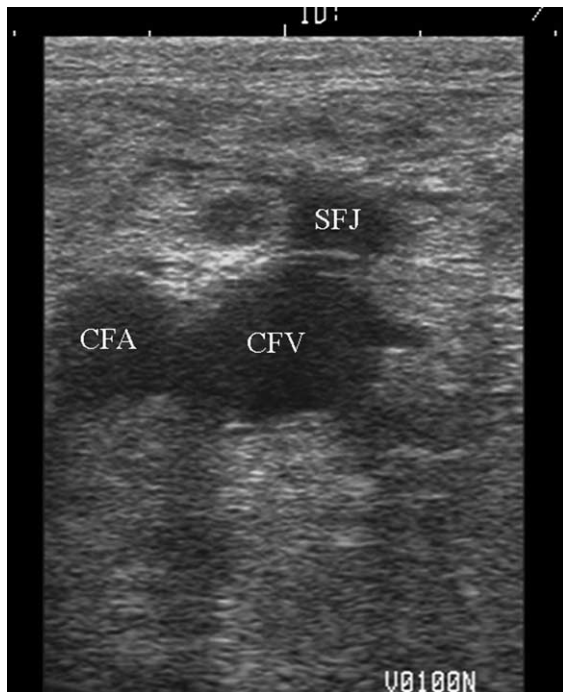

Fig. 3. Transverse view of common femoral vein and artery in the right groin: 'Mickey Mouse' view; CFA, common femoral artery; CFV, common femoral vein; SFJ, sapheno-femoral junction (from the archive of PCS).

known as the 'saphenous eye'. Test every few centimetres for compressibility and reflux.

Measure diameters at the junction and along the GSV if there is reflux. Many authors measure GSV diameter three centimetres below the SFJ. Further useful sites of measurement are at the mid-thigh and at the knee. The measurement should be made of the saphenous trunk vein and not of any varix or dilated

segment with an incompetent valve. Measurement of the diameter can be used to help decide between different types of treatment, for example between (duplex-guided) sclerotherapy, radiofrequency, endovenous laser and surgery. The depth of the saphenous trunk beneath the skin may also be important in patients where radiofrequency closure or endovenous laser therapy is being considered. These measurements can be used as a baseline for follow up after endovenous procedures.

Deep veins in the thigh

The common femoral vein (CFV) should be tested in the longitudinal view for phasic flow with normal respiration, cessation of flow with deep inspiration, possible reflux with the Valsalva manoeuvre, and flow during manual compression of the thigh or calf. This may be better demonstrated with the patient in the supine position. If continuous flow is detected in the CFV, which can indicate a proximal obstruction, it is recommended to extend duplex scanning to the iliac veins and inferior vena cava.

The CFV should be examined above and below the SFJ as retrograde flow in CFV is seen at the SFJ level or higher in the presence of SFJ reflux whereas retrograde flow distal to this level represents true deep venous reflux. It is then necessary to follow the full length of the femoral vein (FV—formerly termed the superficial femoral vein)¹ to the popliteal vein. If necessary, the FV may be better seen by moving the probe to an anterior window through the vastus medialis at the adductor hiatus.

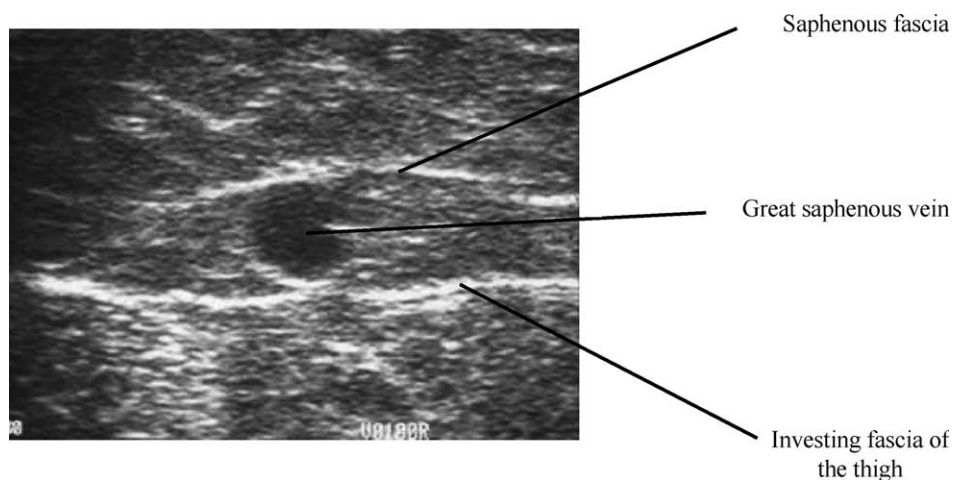


Fig. 4. The 'saphenous eye'—a transverse ultrasound image of the GSV in the thigh showing the fascial components which constitute the saphenous compartment. Other superficial lower limb veins including the AASV and SSV also lie within fascial compartments.

Thigh perforators

It is recommended to look for perforators on the medial aspect of the thigh during the examination of the GSV and the deep veins. Not all thigh perforators, competent or incompetent, will be detected. These are usually found in the middle and lower thirds of the thigh, but can also occur in the proximal thigh near the SFJ. It is necessary to look for lateral and posterior thigh perforators if clinical assessment shows varices in these regions.

Use spectral and/or colour Doppler to test for inward and outward flow in perforators by calf or thigh muscle contraction. Perforating veins which allow bi-directional flow are probably abnormal, although a few non-varicose subjects may have a similar pattern.^{21,22} If an incompetent thigh perforating vein is found then it may be useful to record its diameter measured at the muscle fascia and its location with reference to the knee joint to help decide the best management for this vein.

Protocols for scanning the popliteal vein (PV)

The popliteal fossa is a complex site for investigation, both from the anatomical point of view and for assessment of venous haemodynamics. Multiple longitudinal and transverse views are required. PV is properly scanned with the patient lying in prone position when phasicity of flow with respiration has to be elicited, though some patients may not show this finding also in absence of any abnormality; it is usual to assess flow augmentation with the calf squeezing manoeuvre for the Valsalva manoeuvre is of limited utility at this level. The PV should be examined above and below the SPJ when this is present, as retrograde PV flow is present above the SPJ when the SPJ terminal valve is incompetent, and only retrograde flow distal to this level represents true deep venous reflux. The anatomical and haemodynamic relationship of the PV, SPJ and gastrocnemius veins should be established.

*Protocols for scanning the small saphenous vein (SSV), thigh extension of the SSV and vein of Giacomini**Position of the patient*

Scan the SSV, thigh extension of SSV and vein of Giacomini with the patient standing and facing away, with the knee slightly bent, heel on the ground and weight taken on the opposite limb.

Scanning techniques

Start at the back of the knee. Use a transverse view to identify the major veins of the popliteal fossa.

Determine whether the SPJ is present. If so, show the junction in a longitudinal view. Test the popliteal vein proximal and distal to the SPJ, the gastrocnemius vein insertion and the SPJ for reflux or thrombosis. Determine if there is SPJ incompetence with SSV reflux. SSV reflux may occur during calf muscle contraction or manual calf compression (systolic phase) in some patients suggesting possible popliteal and/or femoral vein obstruction,²³ whereas typically reflux is most obvious during calf release (diastolic phase). If there is reflux, measure the diameter of the SSV 3 cm distal to the SPJ (or at the popliteal crease) and at mid-calf, avoiding any varix in the vein. Measure the level of the SPJ in relation to the popliteal skin crease. The SSV may join the popliteal vein medially, posteriorly or laterally so that it is advisable to record its position in relation to the popliteal vein circumference. Ascertain the presence or absence of an artery accompanying the SSV or the gastrocnemius veins. This is of importance when duplex-guided sclerotherapy is to be undertaken. Look for alternative sources of reflux including communication of the SSV with a popliteal fossa perforator, GSV tributaries, pelvic veins traced to the buttock or perineum, the thigh extension of SSV, or the vein of Giacomini. Look for alternative destinations for GSV reflux including tributaries, the thigh extension of SSV, or the vein of Giacomini.

Scan the thigh extension of the SSV and its connections with deep thigh veins or pelvic veins. The vein of Giacomini is deep to the fascia in most of its course.²⁴ Determine its distal SSV connection and proximal connection into the GSV. Demonstrate the flow direction and show whether there is reflux down from saphenofemoral incompetence to pass to the SSV or up from saphenopopliteal incompetence to pass to the GSV.

*Protocols for scanning veins below the knee**Position of the patient*

Scan for below-knee veins with the patient standing (preferable for superficial veins), or sitting with the foot hanging down resting on the examiner's knee or on a step.

Deep crural veins

With experience, all deep crural veins can be identified. Reflux in the posterior tibial veins (PTVs) best reflects clinical features. Examine PTVs from a medial or posteromedial view and peroneal veins from a posteromedial or posterior view.

These veins should be examined in patients with past or present deep vein thrombosis, and in patients with incompetent perforating veins in the calf. Peroneal veins are the most frequently affected calf veins following previous venous thrombosis.²⁵ Examination of soleal and gastrocnemius veins deep in their muscle groups completes the basic investigation of deep veins in the leg.

Superficial veins of the calf

Examine the GSV in the calf for venous reflux. The GSV in the middle to lower third of the leg is competent in up to 97% of limbs with GSV trunk incompetence²⁶ but the GSV below knee may be incompetent where more proximal parts of the vein are competent and should be investigated. Following varicose vein surgery, incompetence of the GSV below knee may fill varices at the ankle and in the foot. Examine the posterior arch vein (vein of Leonardo) which is a major tributary of the GSV in the leg, search for calf perforating veins that join this vein in the medial calf region, and test for reflux in the vein that may result in medial calf varices.

Calf perforators

Perforators pass through the deep fascia which is a distinct band on the B-mode image. Look for perforators around the circumference of the calf. Not all calf perforators, competent or incompetent, will be detected. If they show outward flow then measure their diameters at the deep fascia and their level from the medial or lateral malleolus. However, diameter measurement alone cannot distinguish competent from incompetent perforators.²⁷ Test for bidirectional flow by colour Doppler or spectral analysis after a distal muscle squeeze or isometric calf muscle contraction. However, no consensus has been reached on the pathological significance of bidirectional flow. Bidirectional flow in a perforator indicates its incompetence, but some authors argue that true pathological incompetence is present only if reflux is elicited during the diastolic phase of calf muscle relaxation or release of compression. Accordingly, some authors suggest testing for inward and outward flow separately during calf muscle contraction or compression and calf muscle relaxation or release to help distinguish pathological from re-entry perforators.²⁸ Assessing approximate duration of inward and outward flow may provide an estimate of the net flow.^{29,30}

Organisation and reporting of tests

The emphasis of an investigation for the morphology and haemodynamic changes in patients with chronic venous disease in the lower limbs is quite different from a test for suspected deep vein thrombosis. The request for the investigation should be made by a physician who has taken a history and undertaken clinical examination to provide valid reasons for the investigation and guidance as to what to look for. Indications for investigation include:

- Primary varicose veins.
- Recurrent varicose veins.
- Skin changes or leg ulceration.
- Other manifestations such as leg swelling or aching.
- Venous malformations.
- Suspected acute deep vein thrombosis.

Reports of results of duplex ultrasound examinations of lower limb veins

The report should state the reason for undertaking the investigation. Inclusion of ultrasound images from the report may be useful to demonstrate the findings but the dynamic nature of the investigation limits the value of still images in most patients. Diagrammatic representation as well as a textual report is far more helpful to express the findings. Video recordings are useful for quality control purposes but video recordings would not normally form part of the report of the investigation.

Reports should detail information regarding venous reflux and development of varices or other aspects of venous disease. This should include the presence of incompetence at each saphenous junction and extent of reflux in each saphenous trunk describing the GSV in the thigh and calf separately where appropriate. The morphology and haemodynamic abnormalities relating to varices and location of diseased veins should be indicated on a diagram. In cases of recurrent varices it is useful to know whether a recurrence has occurred at a previously ligated junction or whether a previously treated saphenous trunk has recanalised. Inclusion of the diameters of diseased veins including saphenous trunks and perforating veins is useful since this may influence the treatment selected for that vein. The report should also include information regarding the morphology of the veins which are hypoplastic, atretic or have been removed at a previous operation.

Deep or superficial veins that have suffered recent or previous venous thrombosis should be described, including the current patency of the vein, indicating

whether the vein remained occluded or has recanalised and whether the recanalised vein has become incompetent and to what extent.

Explanation

The aim of the report should be to convey the full information obtained by the investigator to the clinicians responsible for the patient's treatment. This should greatly influence the management of the patient so that the report should be as unambiguous as possible. This informative process is obviously facilitated if the investigator and clinician responsible for treatment are the same person, but an exhaustive report with a diagram is always suggested for treatment and subsequent follow-up.

Training of personnel conducting venous duplex ultrasound examinations

There is considerable variation between countries as to who actually undertakes the investigation. Registered vascular technologists usually perform these tests in USA and Australia, vascular scientists in UK, and radiologists in many other countries. However, it is common for surgeons, angiologists and phlebologists to perform their own investigations. It is highly desirable that all those personnel involved in performing the investigations undergo systematic training that should include theoretical information, practical training and clinical experience of the investigation recorded in a log book.

Explanation

Reliable information can only be obtained from duplex ultrasound examinations by staff who have a detailed knowledge of the pathological conditions for which they are searching. These will require a comprehensive theoretical knowledge of the subject as well as practical experience for interpreting ultrasound images in such cases.

Acknowledgements

List of the experts who were invited to review this document in San Diego during the Consensus Meeting, or via the internet:

Allegra Claudio (ITA), Antignani P.Luigi (ITA), Bergan John (USA), Bradbury Andrew (GBR), Caggiati Alberto (ITA), Cappelli Massimo (ITA), Cavezzi Attilio (ITA), Chunga Chunga Juan (PER), Clough A. (AUS), Coleridge-Smith Philip (GBR), Creton Denis (FRA), De Simone Juan (ARG), Franceschi Claude (FRA), Gallenkemper Georg (GER), Georgiev Mihael (ITA), Grondin Louis (CAN), Guex J.Jerome (FRA), Jaeger Kurt (SWI), Jeanneret Christina (SWI), Kabnick Lowell (USA), Labropoulos Nicos (USA), Lindhagen Anders

(SWE), Marshall Markward (GER), Morrison Nick (USA), Myers Ken (AUS), Nelzen Olle (SWE), Nicolaidis Andrew (CYP), Partsch Hugo (AUT), Pereira Alves Carlos (POR), Pichot Olivier (FRA), Pieri Alessandro (ITA), Rabe Eberhard (GER), Raymond- Martimbeau Pauline (CAN), Ricci Stefano (ITA), Rilantono Lily I (Indonesia), Schadeck Michel (FRA), Scuderi Angelo (BRA), Somjen George M (AUS), Staelens Ivan (BEL), Strejcek Jaroslav (CZR), Tessari Lorenzo (ITA), Thibault Paul (AUS), Uhl J.Francois (FRA), Van Rij Andre (NZL), Von Planta Irene (SWI), Weiss Robert (USA), Zamboni Paolo (ITA).

The authors express their gratitude to Pierluigi Antignani (webmaster of the UIP website) and to Bernhard Partsch (secretary of the working group) for their collaboration.

References

- 1 CAGGIATI A, BERGAN JJ, GLOVICZKI P, JANTET G, WENDELL-SMITH CP, PARTSCH H. Nomenclature of the veins of the lower limbs: an international interdisciplinary consensus statement. *J Vasc Surg* 2002;36:416-422.
- 2 ALLEGRA C, ANTIGNANI PL, BERGAN JJ, CARPENTIER PH, COLERIDGE SMITH P, CORNU-THENARD A *et al.* The 'C' of CEAP: suggested definitions and refinements. An International Union of Phlebology conference of experts. *J Vasc Surg* 2003;37:129-131.
- 3 EKLOF B, RUTHERFORD RB, BERGAN JJ, CARPENTIER PH, GLOVICZKI P, KISTNER RL *et al.* Revision of the CEAP classification for chronic venous disorders: consensus statement. *J Vasc Surg* 2004;40:1248-1252.
- 4 LABROPOULOS N, LEON M, NICOLAIDES AN, GIANNOUKAS AD, VOLTEAS N, CHAN P. Superficial venous insufficiency: correlation of anatomic extent of reflux with clinical symptoms and signs. *J Vasc Surg* 1994;20:953-958.
- 5 RAUTIO T, PERALA J, BIANCARI F, WIJK H, OHTONEN P, HAUKIPURO K *et al.* Accuracy of hand-held Doppler in planning the operation for primary varicose veins. *Eur J Vasc Endovasc Surg* 2002;24:450-455.
- 6 McMULLIN GM, COLERIDGE SMITH PD. An evaluation of Doppler ultrasound and photoplethysmography in the investigation of venous insufficiency. *Aust N Z J Surg* 1992;62:270-275.
- 7 SOMJEN GM, ROYLE JP, FELL G, ROBERTS AK, HOARE MC, TONG Y. Venous reflux patterns in the popliteal fossa. *J Cardiovasc Surg (Torino)* 1992;33:85-91.
- 8 LEMASLE P, LEFEBVRE-VILARDEBO M, TAMISIER D, BAUD JM, CORNU-THENARD A. Confrontation écho-chirurgicale de la terminaison de la saphène externe dans le cadre de la chirurgie d'exérèse. *Résultats préliminaires Phlébologie* 1995;3:321-327.
- 9 DE SIMONE J. Écho-Doppler couleur de la crosse commune petite saphène—veines jumelles. Aspects anatomiques et hémodynamiques. *Phlébologie* 1998;2:169-177.
- 10 SOMJEN GM, DONLAN J, HURSE J, BARTHOLOMEW J, JOHNSTON AH, ROYLE P. Venous reflux at the sapheno-femoral junction. *Phlebology* 1995;10:132-135.
- 11 FRANCO G. Explorations ultrasonographiques des récives variqueuses post-chirurgicales. *Phlébologie* 1998;51(3):403-413.
- 12 JIANG P, VAN RIJ AM, CHRISTIE R, HILL G, SOLOMON C, THOMSON I. Recurrent varicose veins: patterns of reflux and clinical severity. *Cardiovasc Surg* 1999;7:332-339.
- 13 FISCHER R, LINDE N, DUFF C, JEANNERET C, CHANDLER JG, SEEBER P. Late recurrent saphenofemoral junction reflux after ligation and stripping of the greater saphenous vein. *J Vasc Surg* 2001;342:236-240.
- 14 LEE BB, DO YS, BYUN HS, CHOO IW, KIM DI, HUH SH. Advanced management of venous malformation with ethanol sclerotherapy: mid-term results. *J Vasc Surg* 2003;37:533-538.

- 15 YAMAKI T, NOZAKI M, SASAKI K. Color duplex-guided sclerotherapy for the treatment of venous malformations. *Dermatol Surg* 2000;**26**:323–328.
- 16 SARIN S, SOMMERVILLE K, FARRAH J, SCURR JH, COLERIDGE SMITH PD. Duplex ultrasonography for assessment of venous valvular function of the lower limb. *Br J Surg* 1994;**81**:1591–1595.
- 17 LABROPOULOS N, TIONGSON J, PRYOR L, TASSIOPOULOS AK, KANG SS, ASHRAF MANSOUR M *et al.* Definition of venous reflux in lower-extremity veins. *J Vasc Surg* 2003;**38**:793–798.
- 18 VAN BEMMELEN PS, MATTOS MA, HODGSON KJ, BARKMEIER LD, RAMSEY DE, FAUGHT WE *et al.* Does air plethysmography correlate with duplex scanning in patients with chronic venous insufficiency? *J Vasc Surg* 1993;**18**:796–807.
- 19 PIERI A, VANNUZZI A, DURANTI A, VIN F, CAILLARD Ph, BENELLI L *et al.* Rôle central de la valvule pré-ostiale de la veine saphène interne dans la genèse des varices tronculaires des membres inférieurs. *Phlébologie* 1995;**48**(2):227–229.
- 20 LEMASLE P, UHL JF, LEFEBVRE-VILARDEBO M, BAUD JM, GILLOT C. Veines lympho-ganglionnaires inguinales. Aspects anatomiques et échographiques. Conséquences sur la définition de la néogenèse. *Conséquences thérapeutiques Phlébologie* 1999;**52**:263–269.
- 21 SARIN S, SCURR JH, COLERIDGE SMITH PD. Medial calf perforators in venous disease: the significance of outward flow. *J Vasc Surg* 1992;**16**:40–46.
- 22 LABROPOULOS N, MANSOUR MA, KANG SS, GLOVICZKI P, BAKER WH. New insights into perforator vein incompetence. *Eur J Vasc Endovasc Surg* 1999;**18**:228–234.
- 23 PIERI A, VANNUZZI A, DURANTI A, MICHELAGNOLI S, MARCELLI F, SANTINI M *et al.* La valvule pré-ostiale de la veine saphène externe. *Phlébologie* 1997;**50**(3):343–350.
- 24 RICCI S, GEORGIEV M. Ultrasound anatomy of the superficial veins of the lower limb. *J Vasc Technol* 2002;**26**:183–199.
- 25 LABROPOULOS N, WEBB KM, KANG SS, MANSOUR MA, FILLIUNG DR, SIZE GP *et al.* Patterns and distribution of isolated calf deep vein thrombosis. *J Vasc Surg* 1999;**30**(5):787–791.
- 26 CAVEZZI A. Diagnostic de l'insuffisance veineuse superficielle des membres inférieurs par echo-Doppler-couleur. *Phlébologie* 2000;**1**:15–22.
- 27 YAMAMOTO N, UNNO N, MITSUOKA H, SAITO T, MIKI K, ISHIMARU K *et al.* Preoperative and intraoperative evaluation of diameter-reflux relationship of calf perforating veins in patients with primary varicose vein. *J Vasc Surg* 2002;**36**:1225–1230.
- 28 CAPPELLI M, ERMINI S, TURCHI A, BONO G. Consideration hémodynamique sur les perforantes. *Phlébologie* 1994;**47**(4):389–393.
- 29 BJORDAL RI. Circulation patterns in incompetent perforating veins in the calf and in the saphenous system in primary varicose veins. *Acta Chir Scand* 1972;**138**:251–261.
- 30 STUART WP, ADAM DJ, ALLAN PL, RUCKLEY C, BRADBURY AW. Saphenous surgery does not correct perforator incompetence in the presence of deep venous reflux. *J Vasc Surg* 1998;**28**:834–838.

Accepted 5 July 2005

Available online 14 October 2005